

PATENT FORAMEN OVALE IN A PLASTINATED HEART: AN INNOVATIVE ANATOMICAL ANALYSIS FOR CLINICAL INSIGHTS

FORAME OVAL PATENTE EM UM CORAÇÃO PLASTINADO: UMA ANÁLISE ANATÔMICA INOVADORA PARA INSIGHTS CLÍNICOS

FORAMEN OVAL PERMEABLE EN UN CORAZÓN PLASTINADO: UN ANÁLISIS ANATÓMICO INNOVADOR PARA PERSPECTIVAS CLÍNICAS



10.56238/revgeov17n1-116

Maria Alessamia Nunes Lima¹, Endrya Victoria Lima Brito², Camila Pond Nepomuceno³, Yuri Oliveira Frota de Siqueira⁴, Samara Fernandes e Silva⁵, Fernanda Melo de Carvalho⁶, Silvio Barbosa Matos Junior⁷, Vanessa Moraes da Silva⁸, Manuella Cruz Lira⁹, Kelvis Batista Félix¹⁰, Pedro Kauã Araujo Chagas¹¹, Carlos Reinaldo da Costa¹², Helder Bindá Pimenta¹³

ABSTRACT

Patent foramen ovale is a common anatomical variation in the adult heart, associated with clinical risks such as cryptogenic stroke. This study presents a rare case of PFO observed in a plastinated heart preserved by silicone immersion, allowing detailed three-dimensional analysis. The specimen, obtained from a male donor approximately 45 years old, revealed a PFO measuring 4.2 mm in diameter, with typical features of a potential shunt. Plastination facilitated artifact-free visualization, highlighting atrial asymmetries and their implications for medical education and clinical research. This finding reinforces the importance of integrating anatomy with preventive medicine and suggests future investigations in larger series to correlate morphology with epidemiological data.

Keywords: Patent Foramen Ovale. Plastination. Cardiac Anatomy. Paradoxical Embolism. Medical Education.

RESUMO

O forame oval patente é uma variação anatômica comum no coração adulto, associada a

¹ Medical student. UNL.

² Medical student. UNL.

³ Medical student. UNL.

⁴ Medical student. UNL.

⁵ Medical student. UNL.

⁶ Medical student. UNL.

⁷ Medical student. Faculdade Santa Teresa.

⁸ Medical student. FAMETRO.

⁹ Undergraduated student. Universidade do Estado do Amazonas.

¹⁰ Undergraduated student. Universidade do Estado do Amazonas.

¹¹ Undergraduated student. Universidade do Estado do Amazonas.

¹² Specialist. Universidade do Estado do Amazonas.

¹³ Dr. Universidade do Estado do Amazonas.



riscos clínicos como o acidente vascular cerebral criptogênico. Este estudo apresenta um caso raro de forame oval patente observado em um coração plastinado preservado por imersão em silicone, permitindo uma análise tridimensional detalhada. O espécime, obtido de um doador do sexo masculino com aproximadamente 45 anos de idade, revelou um forame oval patente medindo 4,2 mm de diâmetro, com características típicas de um potencial shunt. A plastinação possibilitou uma visualização livre de artefatos, destacando assimetrias atriais e suas implicações para o ensino médico e a pesquisa clínica. Este achado reforça a importância da integração entre a anatomia e a medicina preventiva, além de sugerir investigações futuras em séries maiores para correlacionar aspectos morfológicos com dados epidemiológicos.

Palavras-chave: Forame Oval Patente. Plastinação. Anatomia Cardíaca. Embolia Paradoxal. Educação Médica.

RESUMEN

El foramen oval permeable es una variación anatómica común en el corazón adulto, asociada a riesgos clínicos como el accidente cerebrovascular criptogénico. Este estudio presenta un caso poco frecuente de foramen oval permeable observado en un corazón plastinado preservado mediante inmersión en silicona, lo que permitió un análisis tridimensional detallado. El espécimen, obtenido de un donante masculino de aproximadamente 45 años de edad, reveló un foramen oval permeable con un diámetro de 4,2 mm, con características típicas de un posible shunt. La plastinación permitió una visualización libre de artefactos, destacando las asimetrías auriculares y sus implicaciones para la educación médica y la investigación clínica. Este hallazgo refuerza la importancia de integrar la anatomía con la medicina preventiva y sugiere futuras investigaciones en series más amplias para correlacionar características morfológicas con datos epidemiológicos.

Palabras clave: Foramen Oval Permeable. Plastinación. Anatomía Cardíaca. Embolia Paradójica. Educación Médica.



1 INTRODUCTION

The foramen ovale (FO) is a physiological interatrial communication in the fetal heart, essential for directing oxygenated blood from the placenta from the right atrium to the left atrium, thereby bypassing the immature pulmonary circulation. After birth, pulmonary expansion and the consequent increase in left atrial pressure typically lead to functional closure of the FO, followed by definitive anatomical closure through fusion of the septum primum and septum secundum in most individuals.

However, in approximately 25–30% of the adult population, this closure remains incomplete, resulting in a patent foramen ovale (PFO), a condition considered a remnant of normal fetal anatomy and classified within the spectrum of atrial septal defects (Hagen et al., 1984; Lechat et al., 1988). Although more than half of infants exhibit PFO at six months of age, spontaneous closure commonly occurs during development.

In adulthood, PFO is usually asymptomatic; nonetheless, under specific hemodynamic conditions, it may allow a right-to-left interatrial shunt, enabling the passage of deoxygenated venous blood and thromboemboli from the venous to the arterial circulation. This paradoxical embolic mechanism underlies several clinical conditions associated with PFO, including cryptogenic stroke, decompression sickness, migraine, platypnea–orthodeoxia syndrome, and peripheral arterial ischemia.

The diagnosis of PFO relies primarily on echocardiographic techniques, and clinical studies have demonstrated that percutaneous closure reduces the recurrence of ischemic stroke in carefully selected patients (Furlan et al., 2012). From an anatomical and educational perspective, plastination—a tissue preservation technique based on polymer impregnation, such as silicone—represents an innovative alternative to conventional fixation methods, preserving three-dimensional architecture, elasticity, and tissue texture with minimal morphological distortion (von Hagens et al., 1987).

This article presents a case of patent foramen ovale identified in a plastinated human heart, exploring its anatomical and clinical implications and highlighting the value of plastination as a tool for medical education and cardiovascular anatomical research.

2 CASE REPORT

This study is a case report based on an anatomical specimen. The heart was obtained from a male donor estimated to be 45 years old, donated for educational purposes, with no available clinical history due to anonymization. Following routine dissection, the specimen was processed using silicone immersion plastination (von Hagens technique), which preserved tissue elasticity and surface texture, enabling manipulation and detailed three-



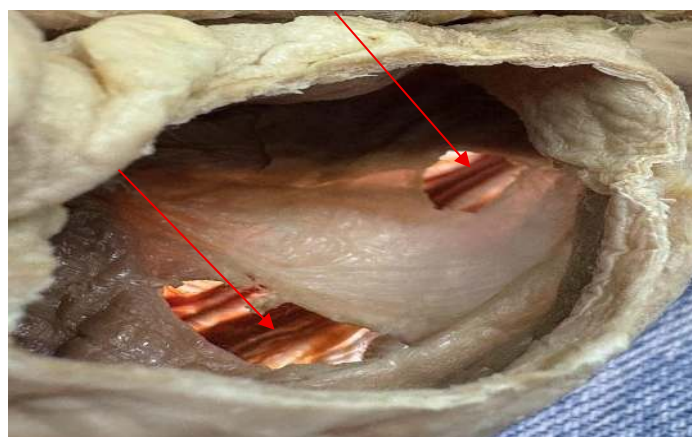
dimensional visualization. Anatomical analysis consisted of macroscopic inspection, precise morphometric assessment using a digital caliper, and comparison with reference plastinated hearts from the same laboratory. The characteristics of the patent foramen ovale (PFO) were documented, including number of openings, diameter, depth, location, and endothelial integrity. No functional or histological analyses were performed, as the focus of the study was purely anatomical. All ethical principles for the use of human anatomical specimens in education and research were observed.

Two distinct oval openings consistent with a patent foramen ovale were identified in the interatrial septum, both located in the inferior portion of the septum primum and establishing communication between the right and left atria. The valve of the foramen ovale, formed by the septum primum, was present but failed to completely seal the defects, allowing for a potential right-to-left shunt. Morphometric evaluation revealed a maximum diameter of 4.2 mm for the larger opening and a depth of 3.5 mm, with the free margin of the septum primum overlapping the septum secundum, resulting in a characteristic valvular tunnel configuration.

The endothelial surfaces of both openings were intact, with no evidence of thrombosis, calcification, or inflammatory changes, suggesting an asymptomatic anatomical condition. When compared with standard plastinated hearts, this specimen demonstrated variation in septal angulation, with a more inferior positioning of the foramen ovale region, a configuration that may facilitate right-to-left shunting under conditions of increased venous pressure. Plastination enabled comprehensive three-dimensional assessment, revealing atrial asymmetry characterized by mild right atrial dilation, thereby integrating the presence of dual PFO openings with subtle variations in overall cardiac morphology (Figure 1).

Figure 1

Left atrial cavity and interatrial septum



Source: Laboratory of Anatomy (2025).



3 DISCUSSION

This case underscores the value of plastination as an advanced preservation technique for maintaining delicate intracardiac structures, such as the patent foramen ovale (PFO), which are frequently distorted, collapsed, or obscured by conventional formaldehyde-based fixation methods. The preservation of structural integrity observed in this specimen enabled precise three-dimensional visualization of the interatrial septum, thereby allowing a more accurate assessment of PFO morphology and spatial relationships.

Given the high prevalence of PFO in the general population, the presence of a right-to-left shunt may have clinically relevant consequences, particularly when embolic material gains access to the systemic circulation, predisposing individuals to paradoxical embolism. PFOs display substantial morphological heterogeneity, encompassing variations in shape, diameter, and septal mobility. Autopsy-based investigations have demonstrated a progressive increase in mean PFO diameter with advancing age, ranging from approximately 3.4 mm in the first decade of life to 5.8 mm in the ninth decade, with larger diameters reported more frequently in women than in men (Hara et al., 2005).

The degree of overlap between the septum primum and septum secundum is a key determinant of PFO length, often resulting in a tunnel-like configuration. Reported tunnel lengths typically range from 5 mm to 13 mm. This anatomical arrangement has important hemodynamic implications, as it may facilitate intermittent right-to-left shunting under specific physiological conditions, such as transient increases in right atrial pressure (Koutroulou, 2020).

From a morphological perspective, PFOs are commonly classified as simple or complex. Complex PFOs are characterized by features including tunnel length greater than 10 mm, association with atrial septal aneurysm, multiple openings on the left atrial side, close relationship with the Eustachian valve or ridge, marked hypertrophy of the septum secundum, or coexistence with additional septal defects, such as atrial septal defect. These anatomical characteristics have been associated with a higher embolic risk, reinforcing the importance of detailed morphological assessment in both anatomical and clinical settings.

Clinically, PFO is considered an incidental finding in up to 25% of autopsy studies; however, its pathological relevance lies in its potential role as a conduit for paradoxical embolism, contributing to systemic ischemic events, particularly cryptogenic stroke (Meissner et al., 2006). Randomized controlled trials have demonstrated that percutaneous PFO closure significantly reduces the risk of recurrent ischemic stroke in carefully selected young patients with cryptogenic stroke, thereby highlighting the clinical importance of recognizing and characterizing this anatomical variant (Saver et al., 2017).



From an educational and research standpoint, the plastinated heart specimen presented in this study constitutes a robust model for anatomical teaching and advanced simulation, effectively bridging classical gross anatomy with clinically relevant pathophysiological mechanisms. The atrial asymmetry observed may reflect subtle hemodynamic adaptations related to chronic variations in atrial pressure or venous return, although the absence of clinical correlation precludes definitive interpretation.

The principal limitation of this study is the lack of clinical and demographic information regarding the donor, which restricts direct correlation between anatomical findings and epidemiological or clinical outcomes. Nevertheless, the high fidelity of structural preservation achieved through plastination provides a strong foundation for future comparative studies involving larger specimen series. Such investigations may further elucidate the relationship between PFO morphology, hemodynamic behavior, and clinical risk.

Overall, these findings emphasize the importance of systematic echocardiographic screening for PFO in high-risk populations, particularly young patients presenting with unexplained ischemic stroke. Moreover, plastination emerges as a powerful and innovative platform for the investigation of cardiovascular anatomical variations, with substantial potential to enhance medical education and support translational research in clinical anatomy.

4 CONCLUSION

The patent foramen ovale observed in this plastinated heart highlights subtle anatomical variations with significant clinical implications, emphasizing the integration between anatomy and modern medicine. Plastination preserves delicate structures, facilitating three-dimensional analyses and educational applications. We recommend further investigations in larger series of plastinated specimens to correlate morphology with clinical epidemiology, aiming at advances in the prevention of cardiovascular complications such as paradoxical embolism.

REFERENCES

- Furlan, A. J., & cols. (2012). Closure or medical therapy for cryptogenic stroke with patent foramen ovale. *New England Journal of Medicine*, 366(11), 991–999. <https://doi.org/10.1056/NEJMoa1009639>
- Hara, H., & cols. (2005). Patent foramen ovale: Current pathology, pathophysiology, and clinical status. *Journal of the American College of Cardiology*, 46(9), 1768–1776. <https://doi.org/10.1016/j.jacc.2005.08.038>



- Hagen, P. T., Scholz, D. G., & Edwards, W. D. (1984). Incidence and size of patent foramen ovale during the first 10 decades of life: An autopsy study of 965 normal hearts. *Mayo Clinic Proceedings*, 59(1), 17–20. [https://doi.org/10.1016/S0025-6196\(12\)60336-X](https://doi.org/10.1016/S0025-6196(12)60336-X)
- Koutroulou, I., & cols. (2020). Epidemiology of patent foramen ovale in general population and in stroke patients: A narrative review. *Frontiers in Neurology*, 11, Article 281. <https://doi.org/10.3389/fneur.2020.00281>
- Lechat, P. H., & cols. (1988). Prevalence of patent foramen ovale in patients with stroke. *New England Journal of Medicine*, 318(18), 1148–1152. <https://doi.org/10.1056/NEJM198805053181802>
- McKenzie, J. A., Edwards, W. D., & Hagler, D. J. (2009). Anatomy of the patent foramen ovale for the interventionalist. *Catheterization and Cardiovascular Interventions*, 73(6), 821–826. <https://doi.org/10.1002/ccd.21889>
- Meissner, I., & cols. (2006). Patent foramen ovale: Innocent or guilty? Evidence from a prospective population-based study. *Journal of the American College of Cardiology*, 47(2), 440–445. <https://doi.org/10.1016/j.jacc.2005.10.044>
- Saver, J. L., & cols. (2017). Long-term outcomes of patent foramen ovale closure or medical therapy after stroke. *New England Journal of Medicine*, 377(11), 1022–1032. <https://doi.org/10.1056/NEJMoa1610057>
- von Hagens, G., Tiedemann, K., & Kriz, W. (1987). The current potential of plastination. *Anatomy and Embryology*, 175(4), 411–421. <https://doi.org/10.1007/BF00309677>

